

# *Results of Lacrimal Duct Injury Treatment at Phrae Hospital: A Comparison between Microscopic and Pigtail Probe Methods*

**Pongsapak Promchot, MD**

*Plastic and Reconstructive Surgery Unit, Department of Surgery, Phrae Hospital, Phrae Province, Thailand*

---

**Abstract**

**Objective:** To comparatively study the management of lacrimal duct injury by microscopic and pig tail probe methods.

**Materials and Methods:** By evaluating the statistical data on 100 lacrimal duct injuries in 100 patients. 50 lacrimal duct injuries were repaired by microscopic method and the other 50 by pigtail probe method.

**Results:** The reduction of operating cost, operating time and hospital stay in patients treated with the pigtail probe method were statistically significant compared with the microscopic method ( $p < 0.001$ ).

**Conclusions:** It is recommended that the lacrimal duct injury be repaired by a pigtail probe method not only to obtain the satisfactory results but also to reduce the operative cost, the operating time and the hospital stay.

---

## **INTRODUCTION**

Epiphora (abnormal overflow of tears down the cheek due to excess secretion of tears or obstruction of the lacrimal duct) will occur if the lacrimal duct laceration is ignored or incorrectly treated. The aim of repairing a lacrimal duct laceration is to re-establish the patency of the damaged system with the least traumatic and the best esthetic results.

Numerous techniques have been used to aid in locating the ends and repairing a severed lacrimal duct.<sup>1-16</sup> Reconstruction of a torn lacrimal canaliculus by passing a thread or a cannula through the distal and

proximal ends of the duct is well known. Problems are often the identification and the approximation of the torn ends of a severed canaliculus when there is bruising and swelling of the lid. In 1962, Worst<sup>17</sup> described the use of a pigtail probe to aid in locating the distal transected end of the canaliculus and fixing to reestablish its continuity.

Since 1968, the pigtail probe has been found to be a valuable aid both in locating the distal end before fixation and reestablishing the continuity of the severed canaliculus by intralacrimal splinting. The operative time in searching for the distal transected end has been markedly reduced. In 1970, Wright<sup>18</sup> obtained

---

**Correspondence address:** Pongsapak Promchot, MD, Plastic and Reconstructive Surgery Unit, Department of Surgery, Phrae Hospital, Phrae Province 54000, Thailand. E-mail: tom\_plastic@hotmail.com

the patency rate of approximately 80% with endocanalicular support direct end-to-end suturing using microscopic method. In 1977, Sauder et al<sup>19</sup> advocated that pigtail probe method should be abandoned in repairing lacrimal duct laceration. However, there was a surgeon factor involved in that study that 20 surgeons were included in reconstructing the severed canaliculi in 51 patients. No single surgeon did more than 5 cases in almost 4 years in the study.

### MATERIALS AND METHODS

From January 1996 to March 2002, 100 patients were admitted to Phrae Hospital for surgical treatment of traumatic canalicular lacerations. All patients were selected at random for methods of surgical treatment. Fifty lesions were repaired by endocanalicular stent-direct, end to end suturing using microscope, the other 50 lesions by pigtail method.

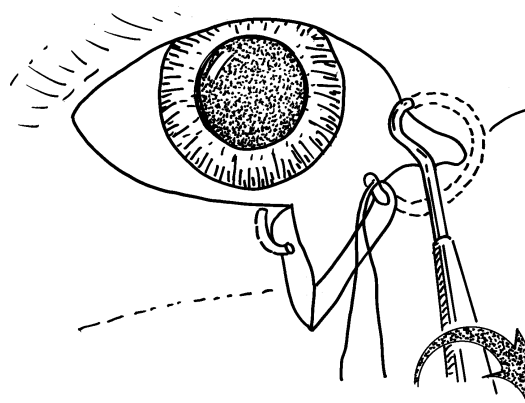
Data including age, sex, causes of injury, eye involved, location of canalicular system damaged, operating time, hospital stay and operating cost were obtained from the medical records.

#### *Technique of Microscopic Method*

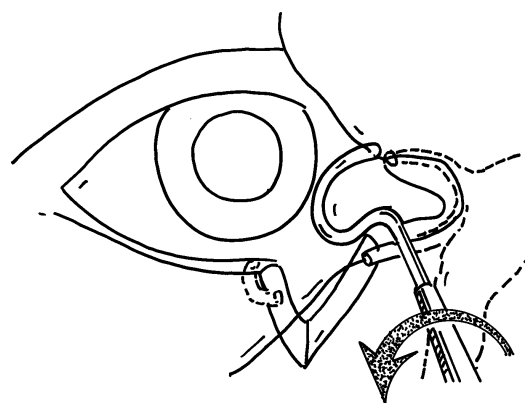
The reconstruction was performed under general anaesthesia in a major operating room. An operating microscope was used for magnifying the operative field. The distal stump of the torn lacrimal duct was identified. The distal and proximal lacerated canalicular stump were anastomosed using 3/0 monofilament suture as a stent.<sup>20</sup>

#### *Technique of Pigtail Probe Method*

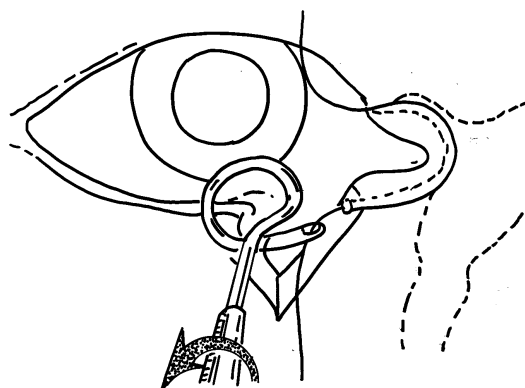
Patients were operated under local anaesthesia in a minor operating room on an out-patient basis. Only a pigtail probe with a suture eye and a suturing set were used for reconstruction. The probe was passed first through the dilated punctum of the uninvolved eyelid, then through the canaliculus, common canaliculus, and came out from the cut medial end of the involved eyelid (Figure 1). Next, a suture material (3/0 dermalon) was passed through the probe's eye and the probe was backed out, leaving the uninvolved system intubated (Figure 2).<sup>20</sup> The probe was then passed through the dilated punctum of the involved eyelid and out the cut lateral end (Figure 3). The lower end of the suture material was threaded through the eye



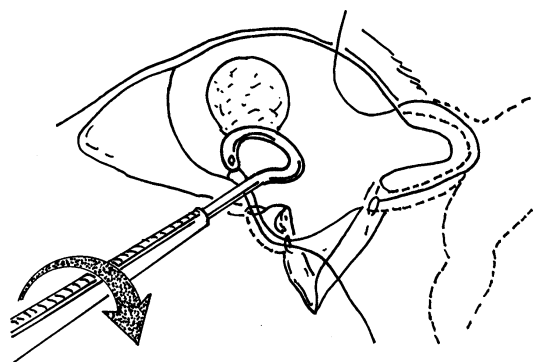
**Figure 1** The probe is passed clockwise first through the dilated superior lacrimal punctum of the uninvolved lid then through the uninvolved canaliculus, common canaliculus and comes out at the cut end of the involved lid. A suture is passed through the eye of the probe.



**Figure 2** The probe is turned anticlockwise pulling the suture along the canalicular system; each end of the suture is left long enough.



**Figure 3** The pigtail probe is then passed anticlockwise through the dilated inferior lacrimal punctum of the involved lid. The eye of the probe comes out at the severed canaliculus and the suture is passed through the probe's eye.



**Figure 4** The pigtail probe is turned back clockwise and the previously placed suture is then pulled out of the inferior lacrimal punctum.

and the probe was backed out to complete the intubation (Figure 4). Both ends of the suture material were knotted, taped to the nonhairy skins, and left in place for three to four weeks until epithelialization of the lacerated lacrimal duct has occurred.<sup>20,21</sup> In no cases were the cut canalicular ends directly sutured. The eyelid margins were closed in layer using 6/0 silk.

## RESULTS

From January 1996 to March 2002, 100 patients were admitted to Phrae Hospital for surgical treatment of traumatic canalicular lacerations. Fifty lesions were repaired by endocanalicular stent-direct, end to end suturing using microscope, other 50 lesions by pigtail method. Patients' age ranged from 4-71 years with the average of 35 years. There were 62 males and 38 females with the sex ratio of M:F = 6:4. The most common cause was motor vehicle accident, others included assaults and dog bites.

The left eyes were involved more often than the right, with inferior left in 52% (52), inferior right 38% (38), superior left 6% (6), and both superior right 4% (4). Regarding the location of canalicular system damage, lacrimal duct was involved in 95% (95/100), nasolacrimal duct in 3% (3/100), and punctum in 2% (2/100)

The operating time in the group using the pigtail probe method averaged 10 minutes which was much shorter than the average of 50 minutes in the group using microscopic method. The length of hospital stay averaged 1.60 days in the group using microscopic methods where as patients in the group using pigtail

**Table 1** Operating time (minutes)

	n	x	SD	t	Sig.
Pigtail probe method	50	10.00	1.42	38.829	0.001
Microscopic method	50	50.00	7.14		

**Table 2** Length of hospital stays (days)

	n	x	SD	t	Sig.
Pigtail probe method	50	0.00	0.00	22.862	0.001
Microscopic method	50	1.60	0.49		

**Table 3** Operating cost (Baht)

	n	x	SD	t	Sig.
Pigtail probe method	50	1200	142.85	46.595	0.001
Microscopic method	50	6000	714.28		

**Table 4** Results of treatment

Results	1 weeks (n, %)	2 weeks (n, %)	3 weeks (n, %)
Good (no epiphora)	85 (85)	96 (96)	100 (100)
Fair (stress epiphora)	6 (6)	1 (1)	0 (0)
Poor (frank epiphora)	0 (0)	0 (0)	0 (0)

probe method were operated as an out-patient. The operating cost averaged 1,600 Baht in the group using pigtail method as compare to 6,000 Baht in the group using microscopic method. The results of treatment were comparable in both groups.

## DISCUSSIONS

Selecting a technique for repair of traumatic canalicular laceration in order to obtain good results, i.e. no epiphora after the repair, is a difficult problem. A comparative study of the repair of torn lacrimal canaliculi was conducted at Phrae Hospital to compare between the results of microscopic method and the pigtail probe method which were performed at random. Good functional results were obtained with both techniques, but the operating time, the operating cost, and the hospital stay decreased in the group using the

pigtail probe method. The pigtail probe method also gave good anatomic results in all cases but sometimes eversion of the lateral part of the lacerated lacrimal duct occurred in the group using microscopic method. The pigtail probe method was performed under local anaesthesia and the patients were discharged home immediately after the operation. This technique was done in a minor operating room. The microscopic technique is performed under general anaesthesia and in a major operating room. The operating time, operating cost and hospital stay were significantly less in the group using pigtail probe method than in the group using microscopic method ( $p < 0.001$ ). The results of this study corresponded with those of Worst<sup>17</sup> and Simon<sup>9</sup>. However, the study by Sauders et al.<sup>19</sup> was debatable because of their 7.3% failure rate and the surgery was performed by 20 different surgeons in 51 repairs. No single surgeon did more than 5 cases in almost 4-year period of the study.

For developing countries, I would recommend that a canalicular laceration be repaired by a pigtail probe method, if the surgeon is skillful and is knowledgeable about the lacrimal anatomy, as the pigtail probe method is very useful if performed by an expert.<sup>21</sup>

#### ACKNOWLEDGEMENT

The author would like to sincerely thank Arthi Kruavit, MD, and Sawithree Thienchai, PhD for their assistance in the preparation of this manuscript.

#### REFERENCES

- Morvion FD. An aid to repair of lacerated tear ducts. *Arch Ophthalmol* 1964; 2: 341
- Kartch MC. French-eye pigtail probe for lacrimal canaliculus repair. *Am J Ophthalmol* 1971; 72: 1145
- Maccord CD Jr. The lacrimal drainage system. *Clinical Ophthalmology*, Duane, Philadelphia: Harper and Row; 1980. p. 1-25
- Kaufman H, Champman R. Modified probe for canaliculus surgery. *Am J Ophthalmol* 1962; 54: 461
- Viers ER. Malleable rods for immediate repair of the traumatically severed lacrimal canaliculus. *Tr Am Acad Ophthalmol & Otol* 1962; 66: 263
- Scheie HG. An Aid to Repair of lacerated tear ducts. *Arch Ophthalmol* 1964; 55: 341
- Shannon GM, Hamdi TN. Repair of injuries of the lacrimal canaliculus. *Am J Ophthalmol* 1966; 62: 974
- Gibbs DC. New probe for the intubation of lacrimal canaliculi with silicone rubber tubing. *Br J Ophthalmol* 1967; 51: 198
- Johnson CC. A canaliculus wire. *Am J Ophthalmol* 1974; 78: 854
- Hanselmayer H. Prognosis of injured canaliculi in relation to elapsed time until primary operation. *Ophthalmologica* 1973; 166: 175
- Hazrati, Ezatollah. Nasolacrimal duct injury after Le Fort I osteotomy. *Plast Reconstr Surg* 1996; 97: 874.
- Kohlaas M, Wiegmann L, Gaszyk M, Water A, Schaudig U, Richard G. Lacrimal duct treatment with ring intubation in injuries of the upper and lower eyelids (in German). *Ophthalmologie* 2001; 98: 743-6
- Kersten RC, Kulwin DR. "One-stitch" canalicular repair. A simplified approach for repair of canalicular laceration. *Ophthalmology* 1997; 104: 2-3.
- Herzum H, Helle P, Hintschich C. Eyelid injuries: epidemiological aspect (in German). *Ophthalmologie* 2001; 98: 1079-82.
- Olver J. Colour atlas of lacrimal surgery. 1<sup>st</sup> ed. Oxford: Butterworth Heinemann; 2001.
- Brigita DO, Matej B. Trauma of the lacrimal drainage system: retrospective study of 32 patients. *Ophthalmology* 2004; 45: 292-4.
- Worst JG. Method for reconstructing torn lacrimal canaliculus. *Am J Ophthalmol* 1962; 53: 520.
- Wright P. *Ophthal Soc. U.K.*, and personal communication 1970; 90: 218.
- Sauders DH, Shannon GM, Flanagan JC. The effectiveness of the pigtail probe method of repairing canalicular lacerations. *Ophthalmic Surg* 1978; 9: 33-40.
- Smiths JW, Aston SJ. Soft tissue injury of the Grabb and Smiths plastic surgery, 4<sup>th</sup> ed. 1991; 1: 332-4.
- McCarthy JG. Reconstruction of the eyelids and associated structures. In: McCarthy JG, editor. *Plastic surgery Vol. 2. The face part 1*. Philadelphia: WB Saunders; 1990. p. 1730-3.